

GP Referred MRI Clinical Guidelines

22102020 VS 3.3

KEY

Assessment Guide

Management Plan

- MRI CONTRAINDICATIONS**
- Pacemaker
- CAUTIONS - CONTACT RADIOLOGY PROVIDER**
- Metalware
 - Cochlear Implants
 - Claustrophobia
 - Works with Metal – Orbit check

***LUMBAR SPINE INJURY**

Clinical Assessment

NO Red Flags

Manage per acute clinical management pathways and guidelines as per references above.

Red Flags – URGENT Referral
Features of Cauda Equina Syndrome – urinary retention, faecal incontinence, widespread neurological symptoms and signs in the lower limb, including gait abnormality, saddle area numbness and a lax anal sphincter
Cauda Equina Syndrome is a medical emergency and requires urgent hospital referral
Infection – Fever plus source of infection, recent surgery, steroids, IV drug use, immunocompromised
Abdominal Aortic Aneurysm
NON URGENT Referral (if fails to improve)
Cancer – History of cancer or strong clinical suspicion
Fracture – Combination of female, over 70 years, steroid use, significant trauma for age and skin abrasion
Spondyloarthropathy – ACR guidelines

Persistent pain 6 weeks post injury that has shown no improvement following initial presentation

BACK DOMINANT PAIN

LEG DOMINANT PAIN

Nociceptive
A) Lower Back Pain; Pain located around spine only.
B) Somatic Referred Back Pain; Pain a dull ache, gnawing. Refers generally to buttock and posterior upper thigh, rarely below the knee. Pain location does not alter once established.

C) Radicular Pain

- Lancing nerve pain radiating down the leg within a narrow confine. Patient uncomfortable at night with this pain.
- +ve SLR / +ve Slump test
- +ve Femoral nerve stretch test (L2/3)

D) Radiculopathy
 Neurological abnormalities consistent with dermatomal or myotomal nerve root distribution +/- reflex abnormalities
 Abnormal neurological exam

X-Ray only if clinical concern regarding pathology

Manage as per local pathways
 Pain Management/
 Community Based Rehabilitation

MRI

NOT CONFIRMED

MRI

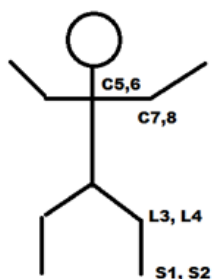
CONFIRMED
 Nerve root involvement

Manage as per local pathways
 Pain Management/
 Community Based Rehabilitation

CONFIRMED
 Nerve root compression

Refer Specialist

Refer Specialist



Nerve	Manual Muscle Testing	Nerve	Dermatome Site
L2/L3	Hip flexion	L2	Lateral aspect upper thigh anteriorly
L3/L4	Knee extension	L3	Medial thigh anteriorly above knee
L4/L5	Ankle dorsiflexion	L4	Medial side of the lower leg or ankle
L5/S1	Ankle plantarflexion	L5	1st web space
L5	Great toe extension	S1	Lateral aspect of the foot
		S2	Posterior aspect calf or thigh in the midline

SLR = Straight Leg Raise Test: positive <70* with high sensitivity. Limited by leg pain and not back pain.